

Module 6 LO5

Pelvic Girdle

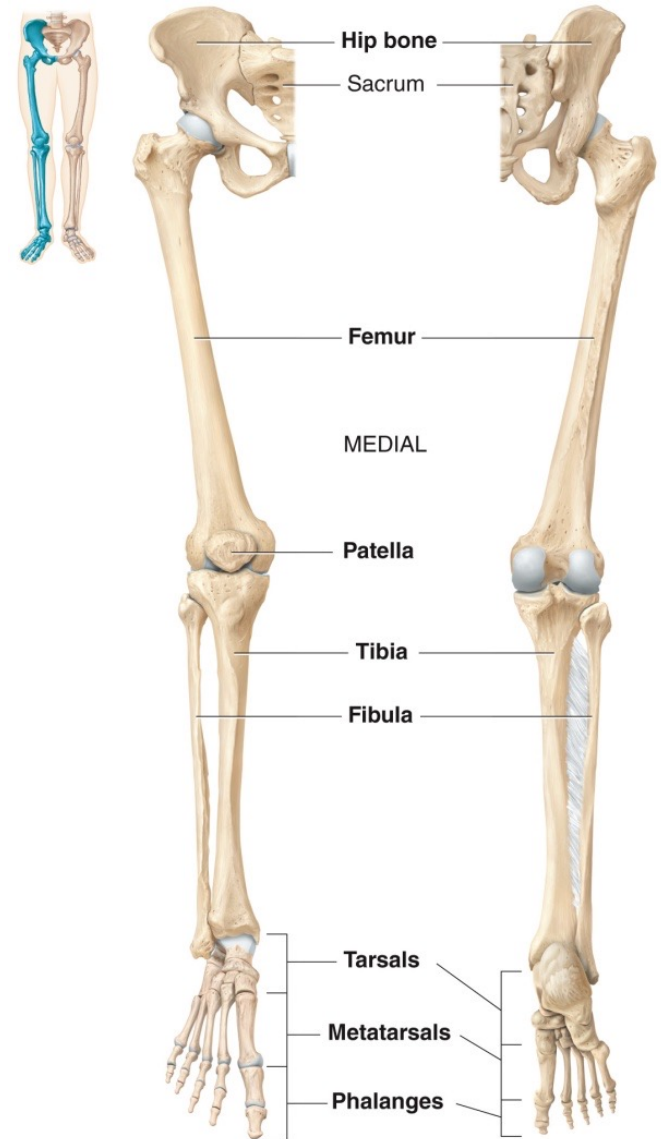
Dr. Lisa Brinn

lbrinn@fiu.edu

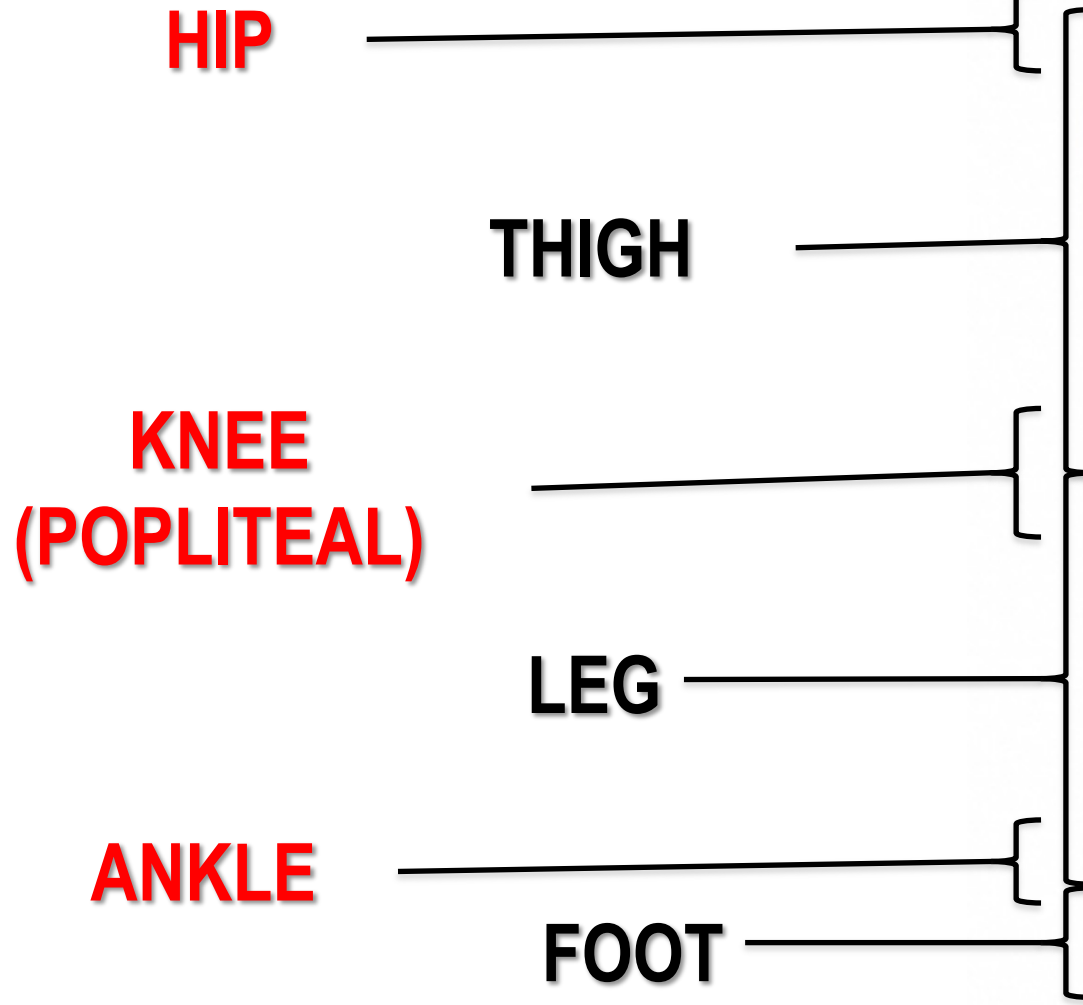
[Link for video recording](#)

5. Lower Limb Bones

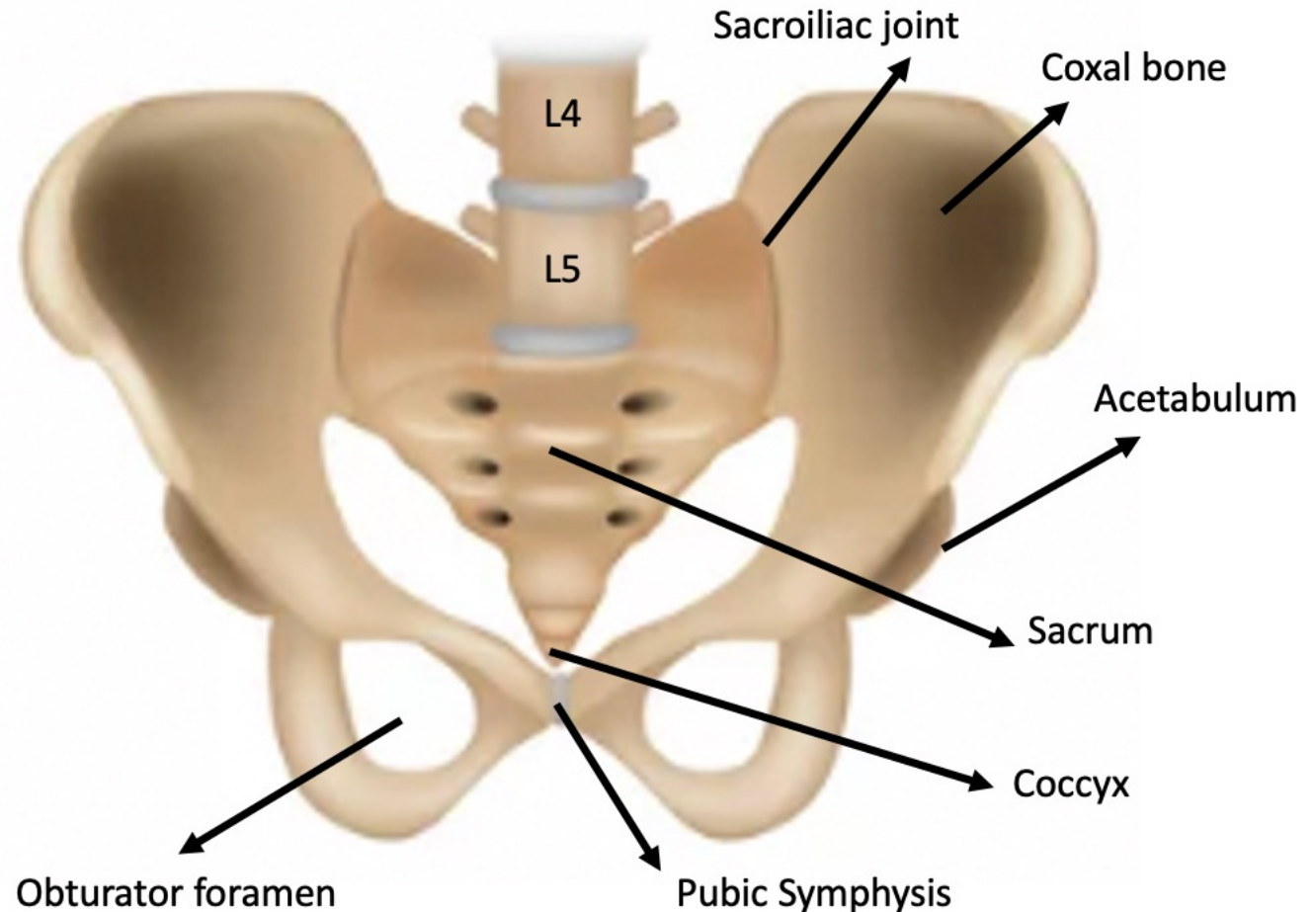
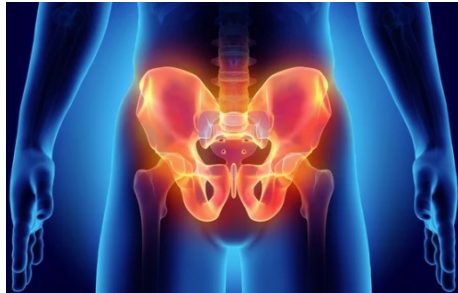- Pelvic girdle
- Free lower limb
 - 1 femur
 - 1 tibia
 - 1 fibula
 - 7 tarsals
 - 19 metatarsals and phalanges



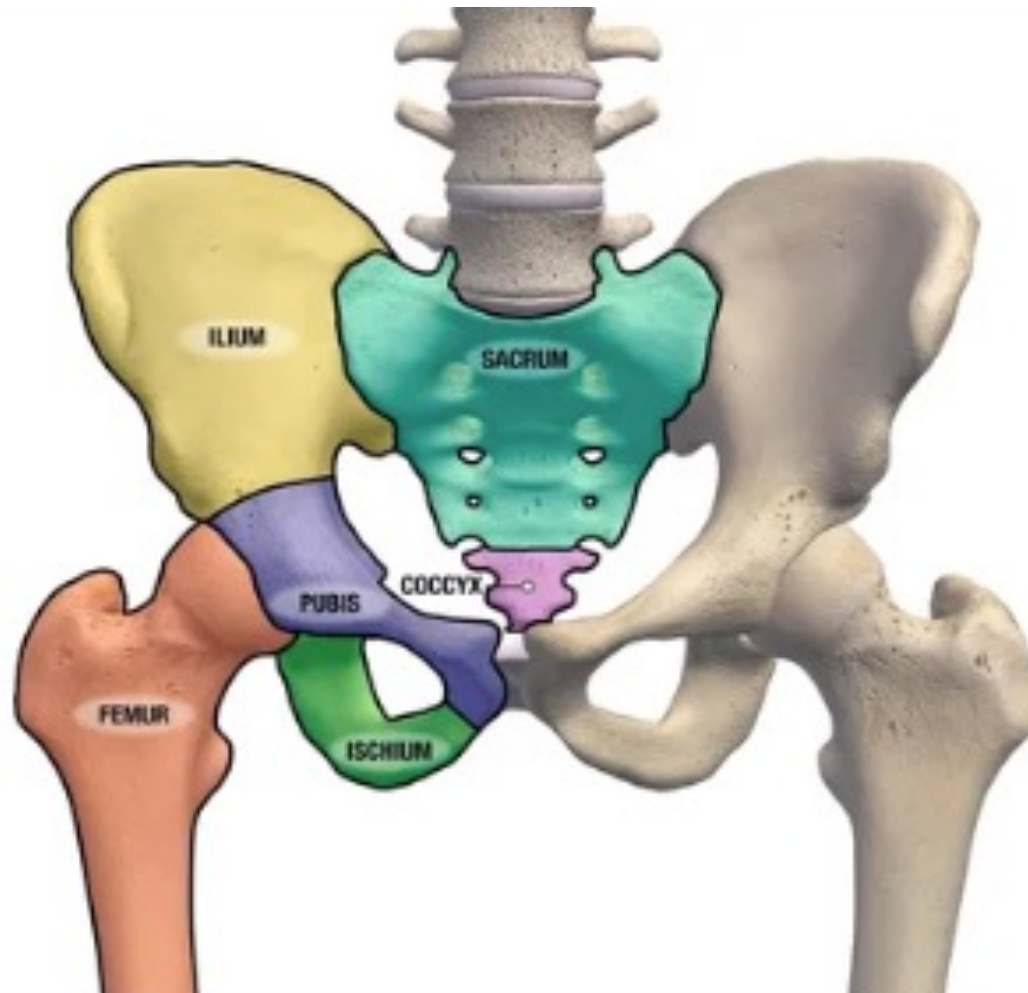
THE LOWER LIMB: REGIONS



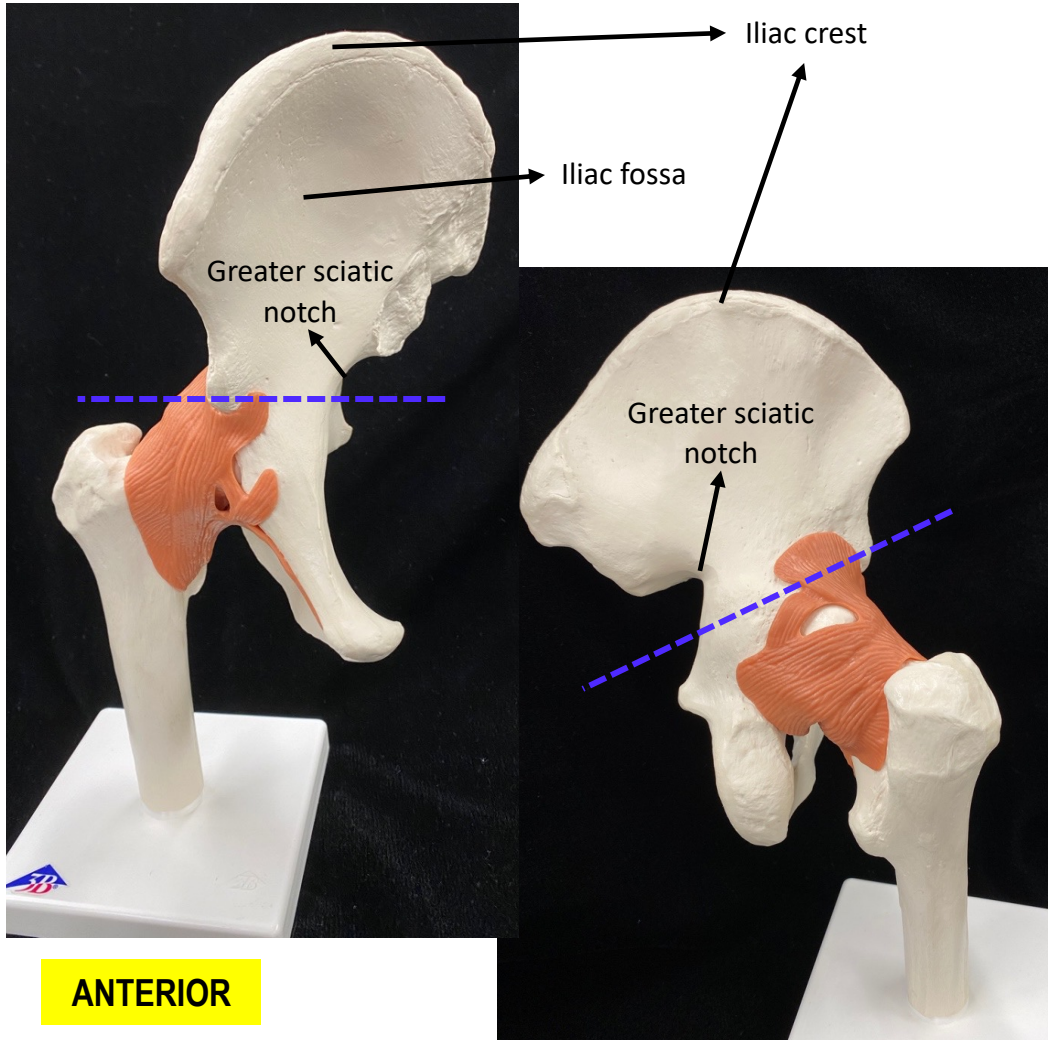
Pelvic Girdle or Os Coxa or Coxal Bone



Pelvic Girdle Bones

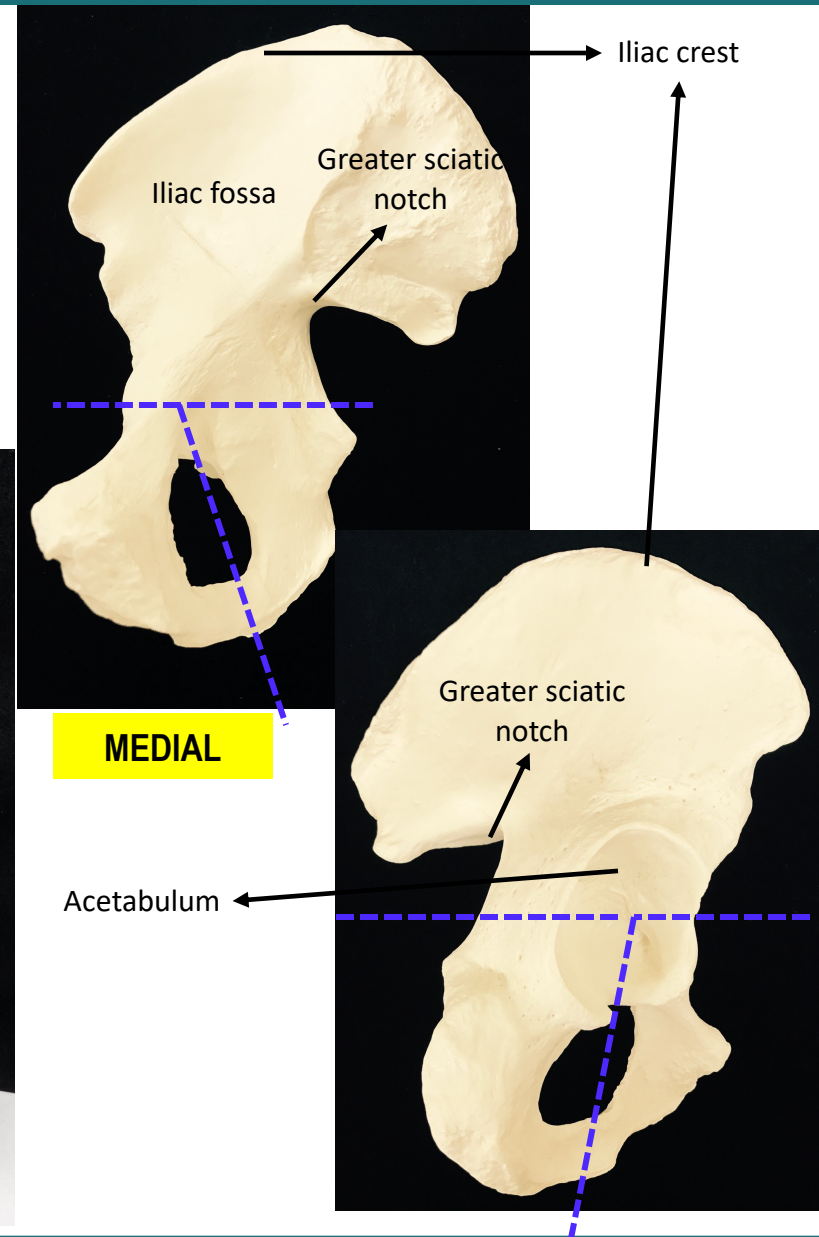


Ilium Bone Features



ANTERIOR

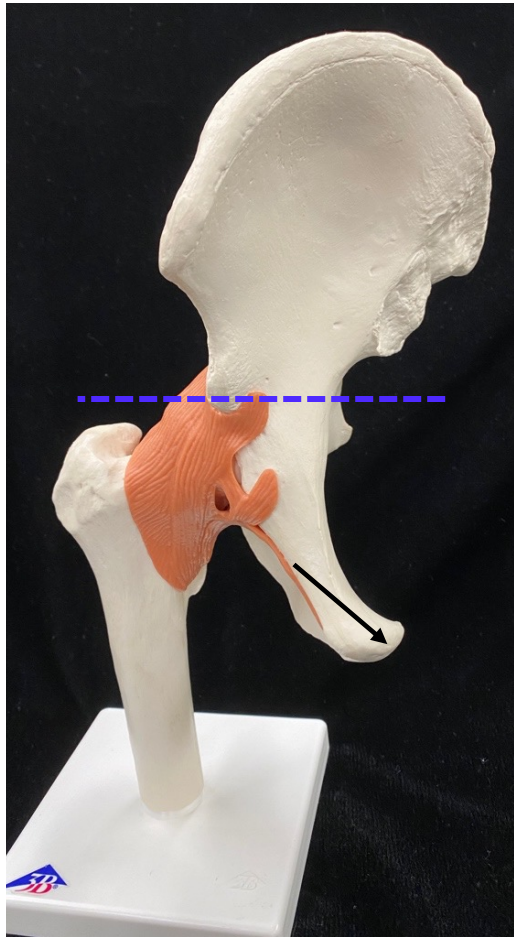
POSTERIOR



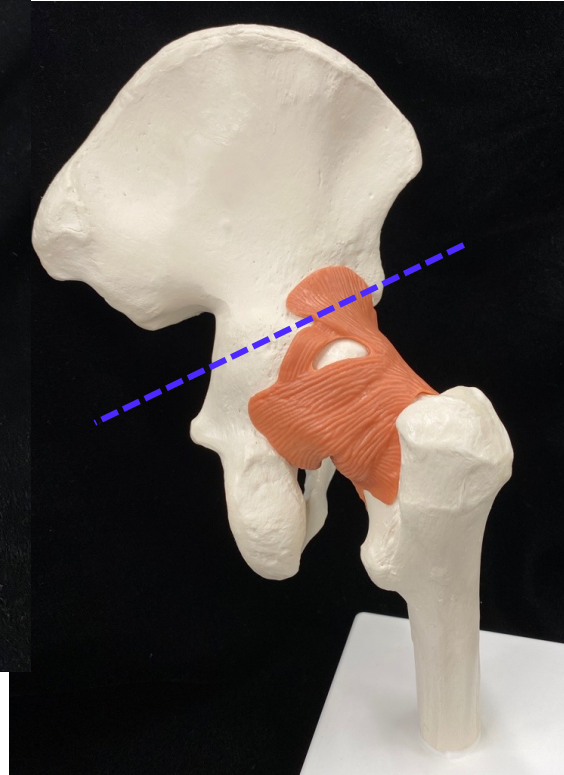
MEDIAL

LATERAL

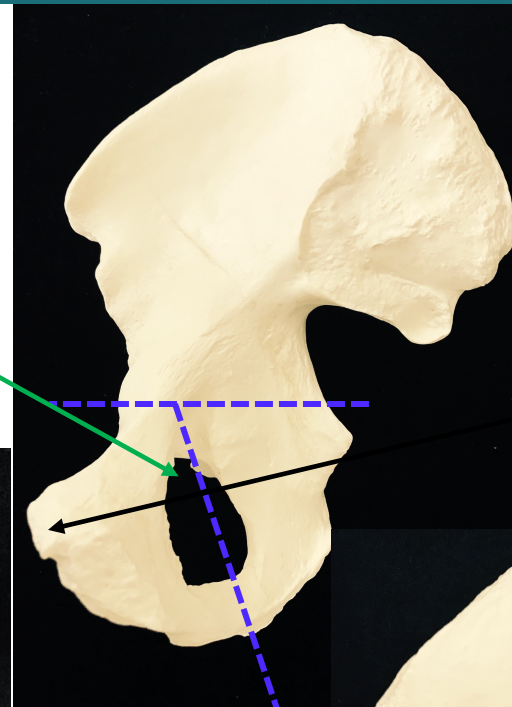
Pubis Bone Features



ANTERIOR



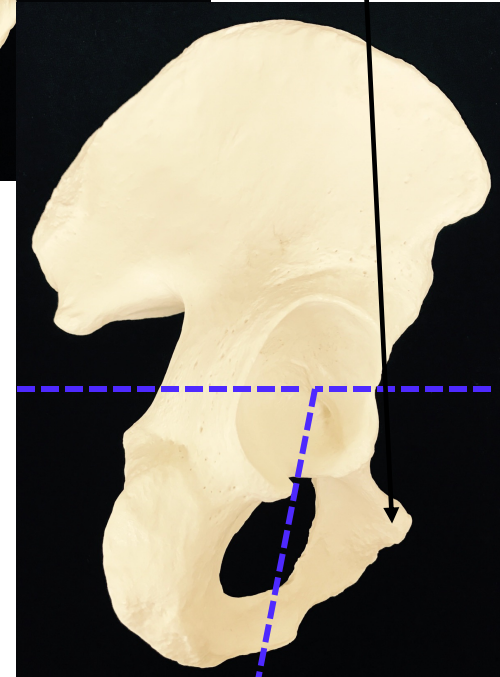
POSTERIOR



MEDIAL

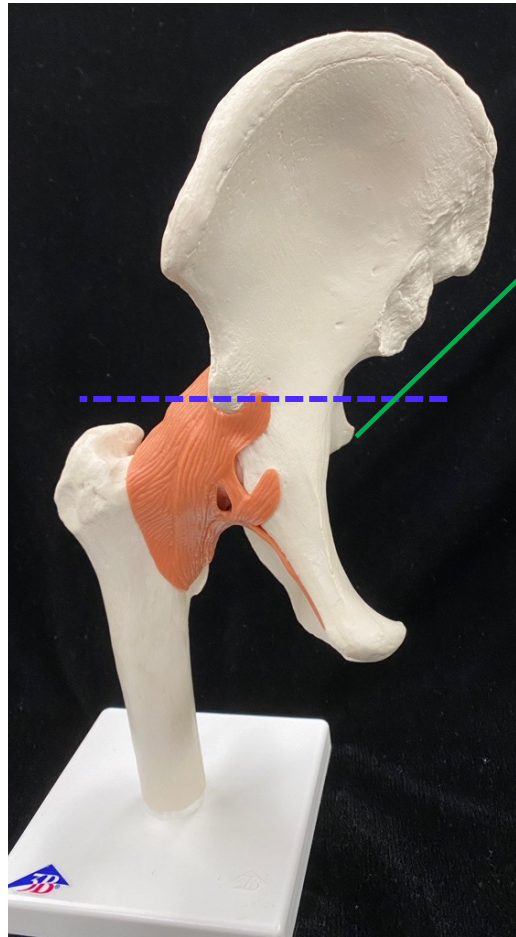
Acetabulum

Pubic symphysis

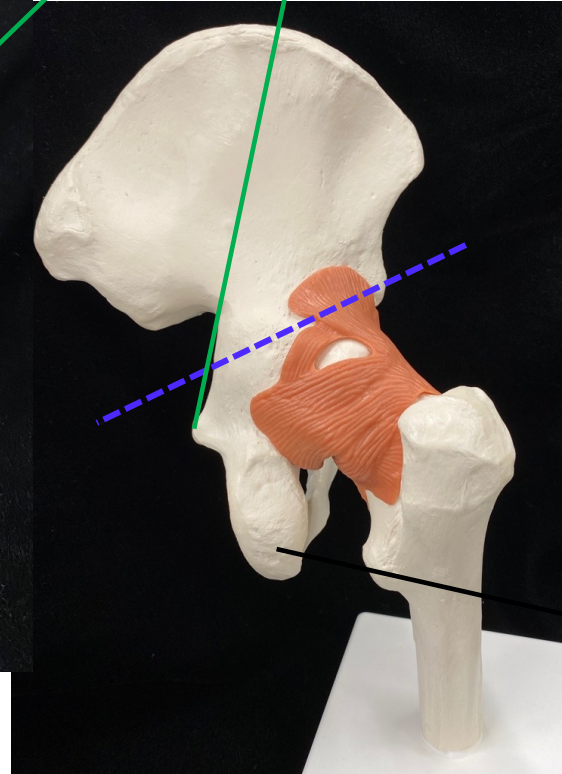


LATERAL

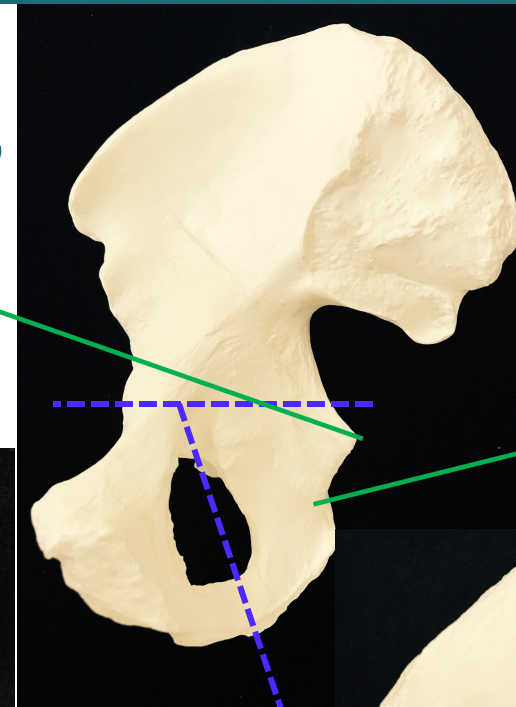
Ischium Bone Features



ANTERIOR



POSTERIOR

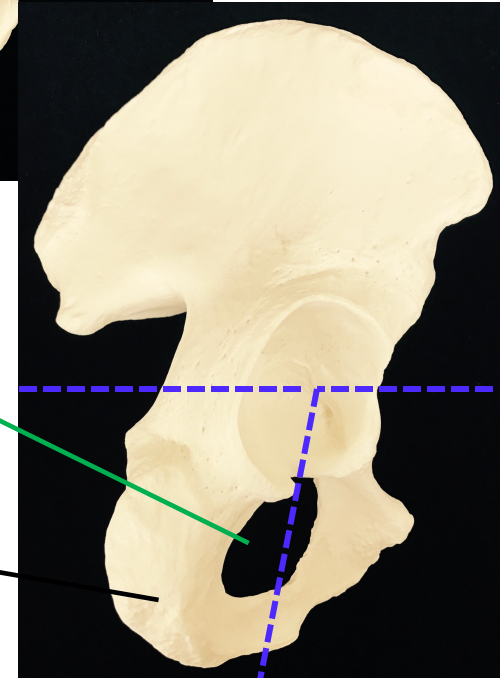


MEDIAL

Obturator foramen

Ischial tuberosity

Lesser sciatic notch



LATERAL